

Intense Pulsed Light and Radiofrequency in The Treatment of Post-Electric Hand Burns in Children

Nader Gomaa Elmelegy^{1*}, Dalia Nader²

^{1*} Department of Plastic Surgery, Tanta University, Station Square, Tanta, ZC 31511, Egypt

² Department of Physical Medicine, Faculty of Medicine, Tanta University, Egypt

ARTICLE INFO

2024 Volume 1, Issue 1
<https://www.doi.org/jdrps.2024.tgc.0267>

Article History:

Received: Feb 01, 2024
Accepted: Feb 03, 2024
Published: Feb 16, 2024

Citation: Elmelegy N, Dalia N. (2024). Intense Pulsed Light and Radiofrequency in The Treatment of Post-Electric Hand Burns in Children. *Journal of Dermatological Research and Plastic Surgery, The Geek Chronicles*. 1(1): 1-13

Copyright: © 2024 Elmelegy N, this is an open-access article distributed under the terms of the Creative Commons Attribution License, which permits unrestricted use, distribution, and reproduction in any medium, provided the original author and source are credited.

Keywords: hand burns. An electric rebuke. Bio-modulation

ABSTRACT

Clinicians and researchers struggle with electrical burns of the hand. To be able to work again after an injury, the patient must have complete hand function and satisfactory cosmetic results.

Between May 2019 and July 2022, 32 hands of 23 patients—16 males and 7 females—with acute electrical burn hand injuries—14 unilateral and 9 bilateral—visited the University's burn center and the author's private clinic. Predictive descriptive research was used in this study. As early excision and grafting have a lot of disadvantages, such as graft hypopigmentation, hyperpigmentation, failure of take, and donor site morbidity, we investigated whether electro-photobiomodulation could shorten hospital stays and result in better outcomes.

A physical examination was carried out by three burn experts who were not connected to this project using a 4-point scale. Of the 32 hands, 11 (34.4%) reported excellent results, 18 (56.2%) reported good results, 3 (9.4%) reported fair results, and none reported terrible results.

Electro-photobiomodulation has more aesthetically pleasing results, requires no hospital stay, and can replace early removal and patching in the treatment of hand injuries caused by electric current.

Introduction

Clinicians and researchers struggle with electrical hand burns. To be able to work again after an injury, the patient must have complete hand function and satisfactory cosmetic results [1].

Children's hands are more susceptible to the passage of electric current and heat than adults' hands because of their anatomical and physiological constitution. Children's skin is thinner and less current-resistant. A more severe injury could arise from this if the infection is not treated, superficial and deep dermal burns run the danger of becoming full-thickness burns and may cause loss of physical function. Treatment of hand electrical injuries, which is still one of the most crucial components of overall patient therapy, must be completed in the least period feasible [2].

Janzekovic (1970) and Jackson and Stone were the first to describe early excision (1972), which has now become the norm to avoid post-burn problems. They admit that early excision and grafting might reduce the length of hospitalization, but they contrast it with late grafting for hand burns. On the other hand, conflicting reports have been made regarding

the advantages of early excision. There is no lengthy effect, according to Goodwin et al. (1983) [3].

There is debate regarding how best to treat the deep dermal hand electrical burns surgically. The pros and cons of early wide excision with immediate reconstruction vs. late, iterative removal and later reconstruction based on various plastic surgery techniques are still being debated [4].

Because electro-photobiomodulation (EPBM) proved to be successful in curing acute deep dermal facial burns, in our university hospital and private clinic, we have started using it in place of traditional therapies for the deep dermal skin burns of the hand [5].

Since we have a long history of using early excision and grafting and have observed a lot of disadvantages such as graft hypopigmentation, hyperpigmentation, failure of take, and donor site morbidity (Fig.1), we decided to investigate whether electro-photobiomodulation could support our initial clinical findings, shorten hospital stay, and result in better outcomes, particularly in terms of avoiding the need for reconstructive surgery and its associated disadvantages.

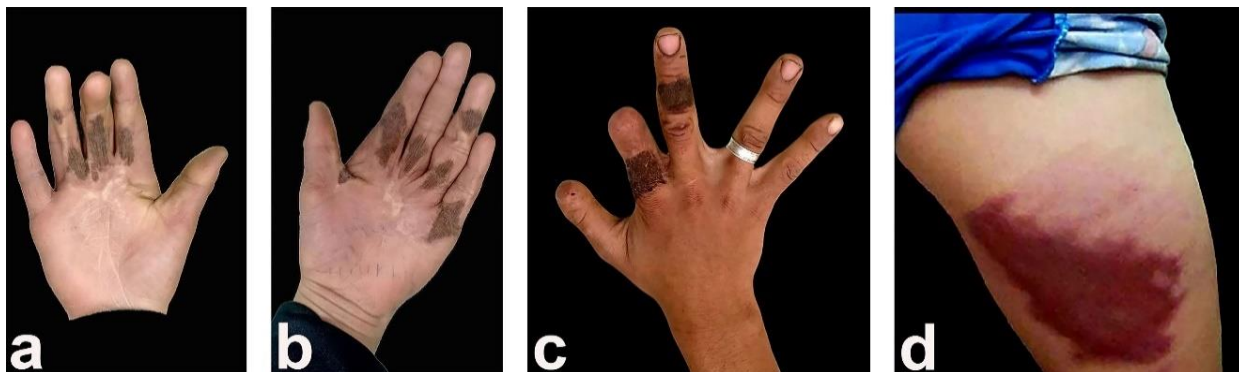

Figure 1 shows documented post-early excision and grafting complications. Hyperpigmentation at the Palmer Hand Surface (A, b) hyperpigmentation at the dorsal hand surface (c) Donor site complication: hypertrophic scar (d)

Materials and methods:

Between May 2019 and July 2022, 32 hands of 23 patients—16 males and 7 females—with acute electrical burn hand injuries—14 unilateral and 9 bilateral—visited the University's burn center and the author's private clinic. Predictive descriptive research was used in this study. The patients' ages ranged between 3 to 15, with a mean age of 7 years.

Inclusion criteria:

Every child under the age of 18 who was presented with either a unilateral or bilateral hand affliction with an electric burn was eligible to take part in the study.

Exclusion criteria:

This group excludes recent superficial burns that recovered quickly. Patients with conditions that affect wound healing, such as photosensitivity, steroid use, collagen vascular abnormalities, and other diseases, were also not included. The study did not include patients who had concomitant burns in other areas of the body.

Before beginning our program of therapy, the patient's hand burns shouldn't have received any additional care. As soon as the patient arrived, the author started (intense pulsed light and radiofrequency) therapies.

The Ethical Research Rules Committee of our institution follow the Public Ethical Guidelines Council of the National Supreme Council of Academic institutions., The study's design and all research techniques that entailed using human subjects were authorized by our institute's ethical committee.

Electrophotobiomodulation was performed for all patients twice a week until full healing took place. All participants undergo the usual daily Tulle gauze and chlorhexidine treatments at an outpatient clinic.

Procedure

For this task, an e-light device with two hands was used. (E light: **E** refers to electricity in the

form of radiofrequency (RF), and **light** refers to intense pulsed light (IPL).

The company in charge of producing it is Beijing Oriental Wison Engineering & Technology Co. A liquid crystal display touch screen has additional layers built on top of the display elements themselves to provide touch functionality and to determine machine settings. The machine's handle allows both IPL and radiofrequency to operate simultaneously with the push of a single button.

The IPL device emits pulsed light with a wavelength between 500 and 1200 nm, a power energy of 0 to 50 j, a pulse width of 1 to 10ms, and a pulse rate of 1-4 Hz.

"In different patients, IPL fluency ranged from 5 to 10 J." The IPL spot diameter is 8 by 32 mm, with pulse delays ranging from 10 to 15 milliseconds. The IPL pulse density in this study was $(6.9 \text{ j cm}^2 \times 2 = 13.8 \text{ j cm}^2)$.

About the radiofrequency (RF) component, the radiofrequency output power is 300 W, the power energy is 0–50 j/cm² - adjustable, the frequency is 600–1500 kHz, there are three pulses per second, the power supply is 220, the radiofrequency fluency varied between 5-7 j, and the RF power density in this study was $(4.7 \text{ j/cm}^2 \times 2 = 9.4 \text{ j/cm}^2)$.

To promote tissue repair, we were operating in stimulatory mode. According to the outcomes of the earlier investigations, we were using a combination of IPL and RF to activate macrophage, keratinocytes, fibrocytes, osteoblast, and osteoclast. Throughout the manuscript, we have cited the sources that were mentioned in that. Two treatments are given to each patient each week. The number of pulses delivered per single treatment was 24-82 pulses per single hand. The duration of each treatment was three to seven minutes per hand spent on each treatment. Each subject received sessions at intervals of 2-4 weeks. The number of sessions that each patient needed was recorded. To avoid skin complications, the pulsed light beam (IPL) element was used with various filters (530 nm, 580 nm, 640 nm, and 755 nm depending on skin color). Once the affected hand lesion has reached sound healing, we

discontinue this form of treatment. Every treatment entails the application of a topical cream containing 2% lidocaine because touching the burned area of the hand with the machine's handles creates a minor amount of pain or discomfort. We have depended on the stimulatory effects of IPL and RF to stimulate macrophages, osteoclasts, which remove dead tissue, and fibrocytes, osteoblasts and keratinocytes, which repair the tissue. Furthermore, angiogenesis is triggered by the stimulatory actions of RF and IP.

Patient pictures and a post-treatment wound assessment were done both during sessions and six months or more after the patient's last session.

The rehabilitation process is a crucial and vital component of post-burn hand care. It begins on the first day of admission and lasts for weeks following the initial incident. A collaborative approach is used to treat burn patients.

According to McCauley RL, a hand contracture examination was done. pediatric burnt hand reconstruction Grade I: Reports symptomatic tightness; no changes are visible; Grade II: Mild reduction in range of motion; Grade III: Functional deficit with light alterations to hand architecture; Grade IV: Significant functional deficit. severe functional impairment and significant alterations to the hand's architecture [6].

All hand functions, including full flexion, extension, adduction, abduction, and thumb opposition of all fingers, were under the supervision of a specialized physiotherapist and examined by three leaders of specialized burn centers who were unaffiliated with this investigation. The outcomes of the preoperative and most recent follow-up pictures were rated on a scale ranging from one to four according to the functional and aesthetic results: excellent, good, fair, and poor. Using a 4-point scale, a thorough hand examination was conducted using the McCauley score and the aesthetic skin appearance of the hand. Patients with a grade 0 McCauley and normal skin quality received an excellent score; patients with a grade 1 McCauley and soft skin quality received good

results; patients with a grade II McCauley and tough skin quality received fair results; and bad results were given to patients with a grade III or IV McCauley score and bad dry, itchy, scaly skin quality.

The level of satisfaction of the clients or their guardians was ascertained using the patient outcome data (PROMs), which are questionnaires used to ascertain the patient's level of fulfillment with the characteristics of expressive shape, return to normal activity, style of living, responses from relatives, and fundamental state of satisfaction. The collected data was organized and totaled. On a scale from 1 (poor), 2 (fair), 3 (good), and 4 (excellent), the individuals were asked to rate their level of contentment with each factor.

Results

The study involved 23 patients in all, with a mean age of 7 years (3–15 years). There were seven female patients and sixteen male patients. For all patients, the cause of injury was a 220-voltage home accident. The electricity transmitted was an alternating current with a frequency of 50 cycles per second. Seven cases of flash injuries and 16 cases of direct contact injuries. The right hand was affected in 11 cases, the left hand was affected in 5 cases, and both hands were affected in 7 cases. Deep dermal burns recovered more quickly than localized full-thickness burns, which in turn recovered quicker than circumferential full-thickness burns. Four patients healed completely in eight days; five patients in eleven days; eight patients in seventeen days; four patients in 37 days; and two patients in 47 days. The number of sessions varied from three to ten. Where three patients healed after three sessions, five patients after six sessions, eight after seven sessions, five patients after nine sessions, and two patients after 10 sessions. Full recovery was observed in every case without the requirement for skin grafting, and the EPBM treatment had no known drawbacks. No patient contracted an infection. None of the patients needed to stay in the

hospital; they were all treated and monitored at an outpatient clinic. In all patients, to treat the burned areas, standard daily dressings with Sofra-Tulle gauze and chlorohexidine were applied daily. We paid attention to the physiotherapist's directions during the follow-up. To maintain range of motion, avoid the formation of contractures, and maximize function, physiotherapy rehabilitation was a crucial part of burn hand care. To maintain extended fingers, it was advised to use hand splints at night. However, only a little dressing was needed to allow the patients to move their fingers as much as possible throughout the day. As regards the skin color according to Fitzpatrick classification, nine patients were type III, 10 patients were type IV, and four patients were type V.

In terms of the part of the hand that was affected, nine patients had only their fingers affected, 19 patients had their fingers and palms affected, and four patients had their dorsum of the hand.

In 93% and 87% of patients, respectively, full range of motion and entire extension restoration of the MP joint and the interphalangeal joints were achieved throughout a 12-month period or longer of follow-up. Of the 32 hands that were affected, 27 could resume their regular activities after one to two months, and five more could do so after three to four months. After one and a half years or more of follow-up, the problems that occurred throughout this study included one patient who experienced hyperpigmentation, one who experienced hypopigmentation, two who experienced hypertrophic scarring, and no one acquired keloid scarring.

According to this study, partial-thickness skin wounds required a minimum recovery time of 8 days while circumferential full-thickness

wounds required a maximum recovery time of 47 days. Beginning around days 1 and 5 (average: day 2.4) after their trauma, participants undergo 3 to 10 EPBM therapies. During days 8 and 47, patients ceased receiving EBPM, and all burns-maintained follow-up management till one year or more.

Photographs were taken before the start of each EPBM treatment. Throughout the trial, the development of the healing process was monitored using professional assessments.

With the notable exception of two cases, the clinical evaluation of the hand burns at follow-up sessions showed no symptoms of a problematic early scar, even for deep dermal and full-thickness burns, which are more likely to develop hypertrophic scars. Unfortunately, the limited number of instances made it impossible to anticipate when a hypertrophic scar would appear.

A hand contracture evaluation using the McCauley RL score revealed Grade I in one case (symptomatic tightness reported; no changes are observed) and Grade II in two cases (little loss of range of motion). There were no cases recorded for grades three or four.

Successful healing depends in large part on wound epithelization. It is managed by a dynamic interaction of several growth factors between epithelium and the supporting stroma. In each instance, radiofrequency and intense pulsed light demonstrated adequate wound achievement outcomes.

A physical examination was carried out by three burn experts who were not connected to this project utilizing a 4-point scale. Of the 32 hands, 11 (34.4%) reported excellent results, 18 (56.2%) reported good results, 3 (9.4%) reported fair results, and none reported terrible results.

Table 1: presented Age, gender, skin color, and filtration type are recognized as important data with varying variability.

The Parameter	The overall patients count (23)	%
patient's age during the first visit:		
< 2 years	0	0%
3 - 6 years	7	30.4%
6-12 Y	11	47.8%
>12 Y	5	21.8%
Gender:		
boys	16	69.6%
girls	7	30.4%
Hand areas involved (32 hands)		
Fingers alone	9	28.1%
fingers and palm	19	59.4%
fingers and dorsum	4	12.5%
skin color:		
Type 3	9	39.1%
Type 4	10	43.5%
Type 5	4	17.4%
Filter type:		
530 nm	7	30.4%
580 nm	9	39.1%
640 nm	4	17.4%
755	3	13.1%

Table 2: displayed Recognized information on clinician acceptance, client experience, and complications experienced.

Variable	Total Number of patients (23)	Percentage
Clinical satisfaction:		
Excellent	8	34.8%
Good	12	52.1%
Fair	3	13.1%
Patient satisfaction:		
Excellent	6	26.1%
Good	12	52.1%
Fair	5	21.8%
Issues that 32 hands experienced:		
Increased pigmentation	1	3.1%
Decreased pigmentation.	1	3.1%
Hypertrophic scar	2	6.3%
Keloid	0	0%

PROMs were used to gauge the degree of satisfaction from the patients or their guardians. Using questionnaires, the patients' pleasure with their appearance, way of life, comments from relatives, and total satisfaction were measured.

A four-point scale was used. Seven patients (30.5%) had excellent outcomes; thirteen (56.5%) had good outcomes; three had fair outcomes; and none had poor outcomes. (Figures 2, 3, 4, and 5).

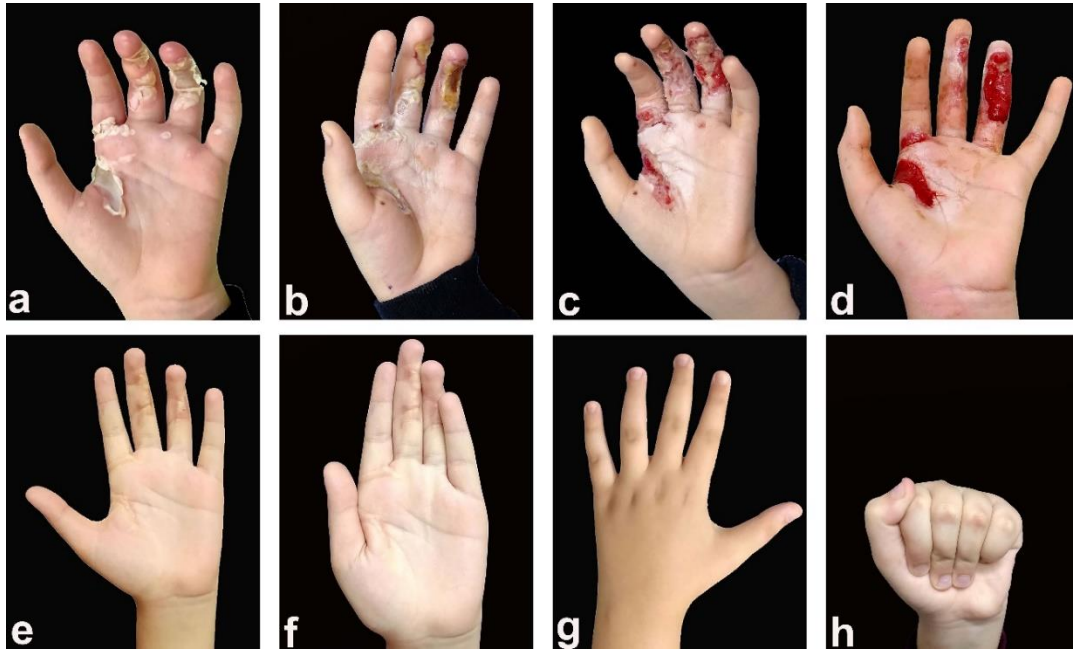


Figure 2 illustrates the healing process after the use of EPBM to treat a deep dermal electric burn to the left hand's palm and fingers (A): one day after the injury; (B), (C), and (D) appearances at 1 week, 2 weeks, and 3 weeks. (e, f, g, and h), after one and a half years of follow-up, the photographs demonstrate a fully functional and remarkable cured left hand.

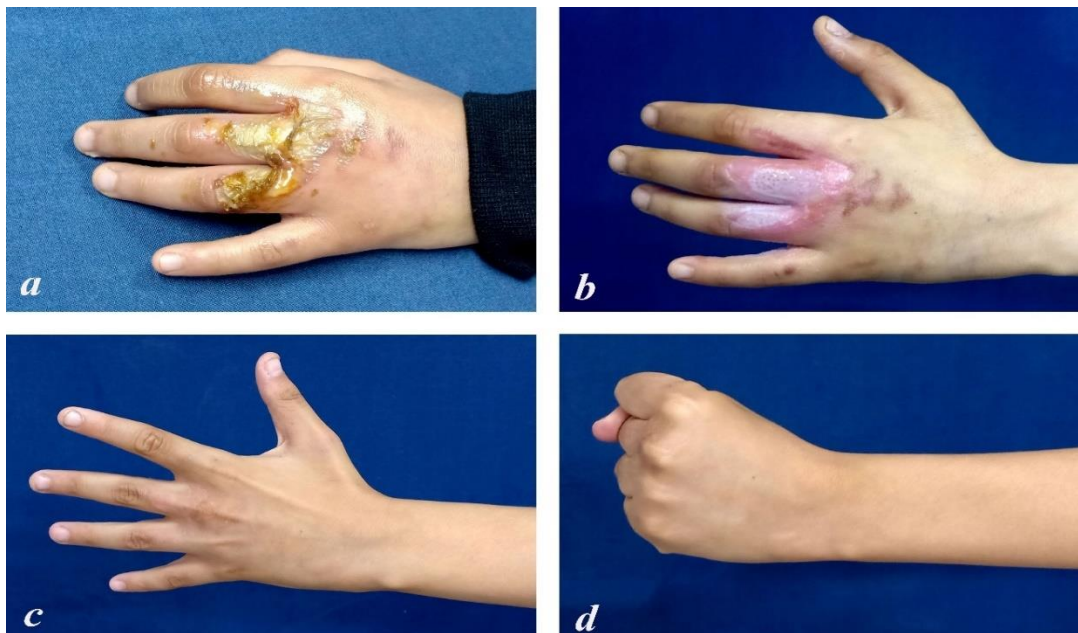


Figure 3 shows the healing process after EPBM was used to treat a post-flash deep dermal electric burn to the fingers and dorsum of the left hand (A), six days later (B), and one year later (C), respectively.

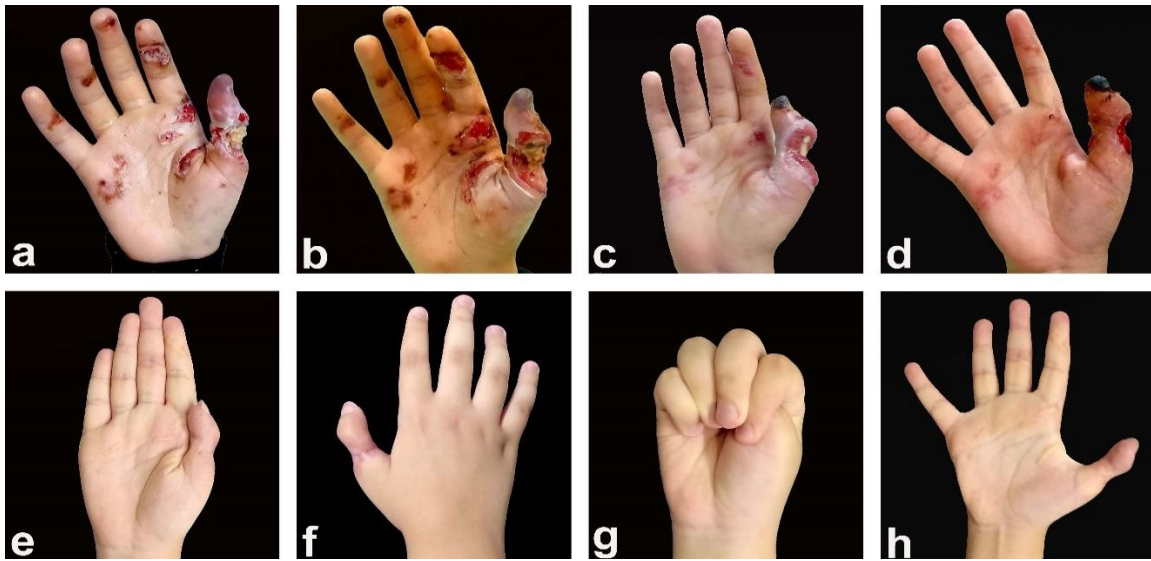


Figure 4 shows the healing process following the application of EPBM to the right hand's palm, fingers, and thumb (A): four days after the injury; (B), (C), and (D) appearances at ten days, twenty days, and one month after the burn injury (e, f, g, and h); during the one and a half years of follow-up, the photographs show a fully functional and effectively healed left hand.

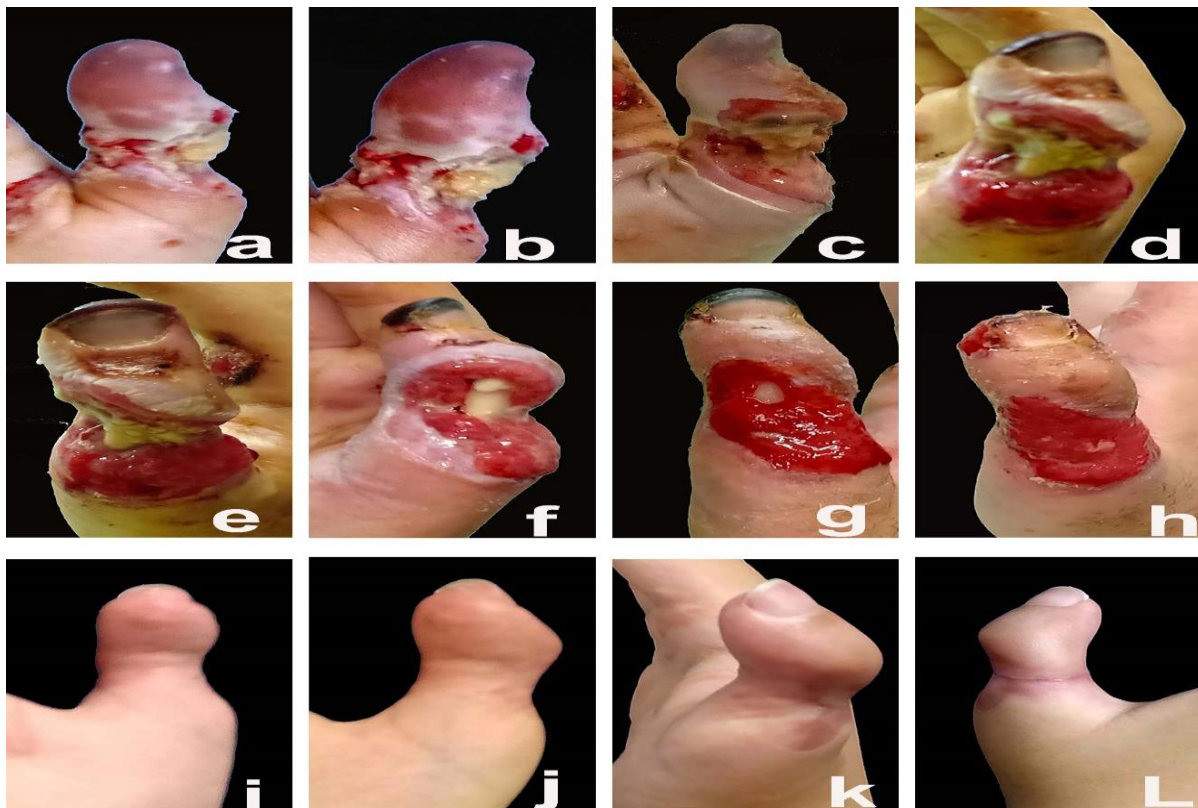


Figure 5 depicts the stages of healing four, ten, thirteen, eighteen, twenty-six, and thirty days after the incident for a thumb with a circumferential deep cutaneous electric burn that was severe and exposed the distal and proximal phalanx bone portions. The images from the 1.5-year follow-up (I, j, k, and l) show a fully recovered and mended right thumb with a minor flexor deformity.

Discussion

For many years, prompt deep dermal hand burn excision and skin grafting have generated debate, and the question of whether early hand grafting is superior to conservative treatment with delayed hand grafting has persisted [7].

For deep dermal burns of the hand, early excision and grafting appear to be widely accepted in the US, but a more conservative technique is typically utilized in Europe.⁶ The results of Nițescu et al [8]. show that timing is important because early excision may result in a shorter hospital stay but may result in over-excision, whereas delayed excision decreases the likelihood of excessive excision but increases the likelihood of wound infection and length of hospitalization [8].

For deep dermal skin injuries, certain authors, including Janzenkovic [9], Jackson, and Stone [10], used tangential excision and rapid grafting as the initial therapies. The authors stressed that rapid closure of this type of excision would lead to reduced scarring and better function. Delay in excision may lead to joint instability and effusion-dynamic retention in fibrous tissue, which together induce the stiffness and degeneration of the metacarpophalangeal joints, according to Peacock et al [11]. It was recommended that the procedure be performed between the second and fifth postburn days.

Two groups of individuals with deep dermal hand injuries were looked at by Abu-Sittah et al [12]. The first set of 34 patients had tangentially excised and skin grafted before the fifth day after burn day, as opposed to the other patients, whose injuries were permitted to granulate before grafting. Patients who underwent early excision had better function and faster healing than other patients, as well as good graft take. According to Ayaz et al. rapid excision and skin grafting were successful in 82 percent of patients who required them when done approximately 80 hours after the injury [13].

Studies by Ali et al [14]. and Hysni et al [15]. found no differences in hand functionality

between the non-operative and early excision and grafting groups. Also, in terms of function, scar generation, daily participation restriction, and general well-being, there were no discernible similarities between these two techniques. The only goal of advising early excision and grafting would be to shorten hospital stays for people who have experienced minor hand deep dermal skin burns.

Because we were worried about hypertrophic scars, we used to conduct early excision and grafting at our department, but we encountered several complications, including graft loss, hypo- and hyperpigmentation, and donor-side morbidity including keloid and hypertrophic scars. Due to these limitations, we investigated the application of electro-photobiomodulation to address problems associated with electric burns.

Leyane et al [16] reported that PBM activates the mitochondria at the cellular level, increasing adenosine triphosphate (ATP) synthesis and triggering the release of growth factors later. In many different cell types, including stem cells and fibroblasts, the binding of growth factors to cell surface receptors triggers signaling pathways that send messages to the nucleus for the transcription of genes that boost cellular proliferation, viability, and motility. Understanding how PBM controls several signaling pathways linked to chronic wound repair has made tremendous strides in recent years. The important part that PBM plays in the activation of many cells signaling pathways involved in wound healing is highlighted in our study.

According to Prado et al [17], it is challenging to determine the ideal technical specifications because studies use a wide range of device settings. Therefore, additional research should be conducted to establish suitable light-use conditions. The various cell types and proteins involved in healing may be stimulated by a low energy density (20 J/cm²), whereas a high energy density (20.6–50 J/cm²) dramatically inhibits cell migration, proliferation, and metabolism.

According to Jere et al [18]. the phases of the physiological process of wound healing overlap. The precise and accurate modulation of cellular responses during wound healing using photobiomodulation depends on growth factors and cytokines. These are accomplished by making use of intricate signaling pathways triggered by cytokines and growth factors. To mention a few, the transcription of genes involved in proliferation and differentiation is regulated by the Janus kinase/signal transducers and activators of transcription (JAK/STAT) pathway.

Naira F. D. et al [19]. examined collagen deposition, fibroblast proliferation, angiogenesis, and wound contraction to assess the efficiency of photobiomodulation treatment (PBMT) in the healing of burn wounds. In deep dermal burn lesions, they came to the observation that PBMT enhanced collagen deposition, revascularization, and tissue repair. de Oliveira RA et al [20] examined the effects of limited Light Emitting Diode (LED) therapy (658 nm) on the recovery of burns in several people. Burns treated with LED exhibited higher epithelization, improved collagen synthesis, enhanced keratinocyte, and fibroblast proliferation, and decreased pain and pruritus. They concluded that the radiation of the damaged limbs recovered clinically more quickly. Along with the rapid growth of the epithelium and granulation tissue, this is also what we saw. The discomfort and itching also lessened.

Jose et al [21]. reported that Numerous studies have demonstrated that, regardless of the conditions or the presence of biomaterials, PBMT has favorable photo-bio-stimulatory effects on bone regeneration, speeding up the process. To enable the proper use of the utilization protocols, the standardization of its use should be further researched as it is still not ideal. In the damaged thumb that was brought to us with exposed necrotic bone, we found that utilizing electrophotobiomodulation assisted in bone remodeling and regeneration.

Brown et al [22] reported that, during a follow-up check conducted 12 months or longer

following the use of PBM revealed that the MP joint and the interphalangeal joints, full range of motion and total extension restoration were accomplished in 93% and 87% of patients, respectively. This is in consistent with our results in which 32 deep dermal burned hands, 27 were able to resume normal activity after two months, and five more hands were able to do so after three to four months. During follow-up, two patients developed hypertrophic scars, which recovered with light therapy after four months.

In our study, electrophotobiomodulation was used as soon as the patient visited our department or an outpatient clinic. There was no skin grafting used. We were able to accomplish adequate healing and good function while also avoiding all the donor and recipient complications associated with skin grafts. The mechanism of action of electrophotobiomodulation was through stimulation of macrophage to help of rapid debridement of the necrotic tissue, also stimulation of fibrocyte to lay down collagen, stimulation of osteoclast to remove necrotic bone, stimulation of osteoblast to help in the new bone formation and simulation of the keratinocytes for induction of rapid proliferation.

We did not do any surgical procedures, but we did develop a method for electro-photo-bio modulating macrophages to remove dead tissue. By using electrophotobiomodulation, we have also stimulated a range of cell types and helped tissue repair. We have cited past studies by different authors throughout the publication [17,18,19]. In our work, dead tissues were not removed surgically; instead, electrophotobiomodulation stimulation was used to improve the physiological properties of many cell types, including macrophages, fibrocytes, and keratinocytes. This resulted in a very beneficial outcome because it made it possible to remove the dead tissue without bleeding and to speed up the healing process.

IPL (intense pulsed light) devices emit polychromatic, incoherent, high-intensity pulsed light with predetermined wavelength

spectrum, fluence, and pulse duration using flashlamps and bandpass filters. IPL devices operate on a fundamentally similar basis to lasers in that the target is selectively thermally damaged. A variety of skin problems can be treated using the recommended wavelengths, fluences, pulse lengths, and pulse intervals together [23].

As is the range of IPL technology, particularly with regard to various wavelength filters, pulse durations, pulse frequencies, and cooling modalities to guard against side effects, using intense pulsed technology in different skin color types is an extremely versatile, safe, and effective modality for the treatment of vascular and pigmented lesions [24].

To prevent possible IPL skin complications, filters must be used during IPL on various types of skin. Different chromophores, molecules that absorb light of a certain wavelength and transform it into thermal energy, are present in the skin. This idea is crucial when using IPL on individuals with darker skin tones since extra care must be taken to ensure their safety and avoid dyschromia. Patients with darker skin may benefit from choosing filters that pass longer wavelengths that penetrate deeper and spare the epidermis because melanin tends to absorb light at shorter wavelengths. Given the same theory, patients with lighter skin can successfully treat pigmented lesions with filters that pass a shorter wavelength [25]. In our study, we avoided IPL problems by using filters with wavelengths of 530 nm in seven patients, 580 nm in nine patients, 640 nm in four patients, and 755 nm in five patients, depending on the skin color of each patient.

Deep dermal and full-thick facility and patient care is resource-intensive, frequently performed in a specialist facility, and has a significant influence on not only the patient's life but also the lives of caregivers and families—often for a protracted length of time. According to a recent study, burn injuries have an impact on mortality and morbidity for at least 5 to 10 years following the damage [26]. Even though we used a novel form of treatment—electrophotobiomodulation—and had a small

number of cases to work with, our results—which included complete recovery of hand function in a short period of time—were rapid when compared to those of other studies. They ranged from 8 to 47 days.

At any age, the resulting loss of hand function due to burn trauma can have a devastating impact on the patient's many roles in life, particularly their employment status and active work life. Early therapy following hand burn trauma aims to maintain mobility, stop contracture from forming, and promote hand functionality as well as a pleasing aesthetic outcome. The potential side effects of a hand burn injury include joint contractures, loss of range of motion (ROM), and disabling functional impairments like neuropathy and amputation [27].

Physical, psychological, and social elements of care are all included in post-burn hand rehabilitation, and it is normal for burn patients to struggle in one or more of these areas after suffering a burn injury. A patient with severe disabling and deforming contractures brought on by burns may experience significant handicap if ignored [28].

In our study, from the first day following the burn and even months after full healing, physiotherapist practiced post-burn hand rehabilitation. Our goals in burn rehabilitation are to maximize functional capacity, maximize psychological well-being, and maximize social integration while minimizing the negative impacts of the injury in terms of maintaining range of motion, decreasing contracture formation, and minimizing the impact of scarring.

Limitations for the current work:

To avoid major consequences from the use of either powerful pulsed light, radiofrequency, or both, electrophotobiomodulation must be performed by a highly qualified professional when treating post-electric burn hands, especially in people with diverse skin tones.

Conclusions

Electro-photobiomodulation encourages the rapid formation of granulation tissue and epithelial cover in post-electric burn problems. Electro-photobiomodulation, which has a more aesthetically pleasing appearance and requires no hospital stay, can replace early removal and patching in the treatment of hand injuries caused by electric current.

Electro-photobiomodulation prevented problems at the donor location by eliminating the need for skin grafts.

Declarations

Supporting and sponsoring financially
There was no money taken from any place. Any financial or material support or compensation for the study is given to the authors, the burn center, and/or the patients.

Competing Interests

The authors had no conflicts of concern to disclose.

Participant Agreement and ethical clearance

The techniques used in this study were approved by the institutional and national research councils and in conformity with the 1964 Helsinki Declaration and any subsequent amendments or ethical standards. In this study, the standards and guidelines of ethical and professional conduct have been upheld.

All patients who took part in the trial provided permission, and further consent was sought from each participant whose name is mentioned in this publication.

Evidence Level: IV Clinical Research.

References

1. Jeschke MG, van Baar ME, Choudhry MA, et al. Burn injury. *Nat Rev Dis Primers*. 2020 Feb 13;6(1):11.
2. Grossova I, Zajicek R, Kubok R, et al. The treatment of palmar contact burns in children: a five-year review. *Ann Burns Fire Disasters*. 2017 Mar 31;30(1):5-8
3. Omar T, and Ahmed A. Evaluation of hand function after early excision and skin grafting of burns versus delayed skin grafting: a randomized clinical trial. *Burns: Burns* 2011, Jun;37(4):707-13.
4. Z Crkvenjas, J Tymonová, M Adámková, et al. Surgical treatment of electrical burns by local flap plastic surgery. *Acta Chir Plast* 2005;47(1):10-2.
5. Nader Gomaa Elmelegy. Aesthetic treatment of acute burns of the face using electro-photobiomodulation. *J Burn Care Res*. 2023 Jan 27; irad009.
6. McCauley RL. Reconstruction of the pediatric burned hand. *Hand Clin*. 2009 Nov;25(4):543-50. doi: 10.1016/j.hcl.2009.06.011. PMID: 19801126.
7. M Saaiq 1, S Zaib, S Ahmad. Early excision and grafting versus delayed excision and grafting of deep thermal burns up to 40% total body surface area: a comparison of outcome. *Ann Burns Fire Disasters*. 2012 Sep 30; 25(3):143-7.
8. Nițescu C, Calotă DR, Florescu IP, et al. Surgical options in extensive burns management. *J Med Life*. 2012 Oct-Dec;5(Spec Issue):129-136.
9. Janzekovic Z. A new concept in the early excision and immediate grafting of burns. 1970 Dec;10(12):1103-8.
10. Jackson DM, Stone PA. Tangential excision and grafting of burns. The method, and a report of 50 consecutive cases. *Br J Plast Surg*. 1972 Oct;25(4):416–426.
11. Peacock EE, Madden JW, Trier WC. Some studies on the treatment of the burned hand. *Ann Surg*. 1970; 171:903–914.

12. Abu-Sittah GS, El Khatib AM, Dibo SA. Thermal injury to the hand: a review of the literature. *Ann Burns Fire Disasters*. 2011 Dec 31;24(4):175-85.
13. Ayaz M, Bahadoran H, Arasteh P, et al. Early Excision and Grafting versus Delayed Skin Grafting in Burns Covering Less than 15% of Total Body Surface Area; A Non- Randomized Clinical Trial. *Bull Emerg Trauma*. 2014 Oct;2(4):141-5.
14. Ali Mohammadi, Ali B, Saeed M, Early excision, and skin grafting versus delayed skin grafting in deep hand burns (a randomized clinical controlled trial). *Burns*. 2011 Feb;37(1):36-41.
15. Hysni M, Shkelzen B, Violeta K Z, et al. A retrospective study of 572 patients with hand burns treated at the Department of Plastic Surgery Kosovo during the period 2000-2010. *Int J Burns Trauma*. 2014; 4(1): 7–13.
16. Leyane TS, Jere SW, Houreld NN. Cellular Signaling and Photobiomodulation in Chronic Wound Repair. *Int J Mol Sci*. 2021 Oct 18;22(20):11223. doi: 10.3390/ijms222011223. PMID: 34681882; PMCID: PMC8537491.
17. Prado TP, Zanchetta FC, Barbieri B et al Photobiomodulation with Blue Light on Wound Healing: A Scoping Review. *Life (Basel)*. 2023 Feb 18;13(2):575. doi: 10.3390/life13020575. PMID: 36836932; PMCID: PMC9959862.
18. Jere SW, Abrahamse H, Houreld NN. The JAK/STAT signaling pathway and photobiomodulation in chronic wound healing. *Cytokine Growth Factor Rev*. 2017 Dec; 38:73-79. doi: 10.1016/j.cytogfr.2017.10.001. Epub 2017 Oct 6. PMID: 29032938.
19. Naira F D, Nilton A, Carlos Z, et al Photobiomodulation Therapy in Burn Wound Healing: Systematic Review and Meta-Analysis of Preclinical Studies. *Photobiomodul Photomed Laser Surg*. 2021 Jul;39(7):439-452.
20. de Oliveira RA, Boson LLB, Portela SMM et al. Low-intensity LED therapy (658 nm) on burn healing: a series of cases. *Lasers Med Sci*. 2018 May;33(4):729-735. doi: 10.1007/s10103-017-2399-z. Epub 2017 Dec 4. PMID: 29199384.
21. Jose S, Maria G, Marcelie P, Photobiomodulation therapy (PBMT) in bone repair: A systematic review. *Injury* vol. 50,11 (2019): 1853-1867.
22. Brown M, Chung KC. Postburn Contractures of the Hand. *Hand Clin*. 2017 May;33(2):317-331. doi: 10.1016/j.hcl.2016.12.005. Epub 2017 Mar 1. PMID: 28363298.
23. Babilas P, Schreml S, Szeimies RM et al. Intense pulsed light (IPL): a review. *Lasers Surg Med*. 2010 Feb;42(2):93-104. doi: 10.1002/lsm.20877. PMID: 20166155.
24. Goldberg DJ. Current trends in intense pulsed light. *J Clin Aesthet Dermatol*. 2012 Jun;5(6):45-53. PMID: 22768357; PMCID: PMC3390232.
25. Tanzi EL, Lupton JR, Alster TS. Lasers in dermatology: four decades of progress. *J Am Acad Dermatol*. 2003 Jul;49(1):1-31; quiz 31-4.
26. Mason SA, et al. Increased rate of long-term mortality among burn survivors. *Ann. Surg*. 2019; 269:1192–1199. doi: 10.1097/SLA.0000000000002722.
27. Kara S, Seyhan N, Öksüz S. Effectiveness of early rehabilitation in hand burns. *Ulus Travma Acil Cerrahi Derg*. 2023 Jun;29(6):691-697. doi: 10.14744/tjtes.2023.22780. PMID: 37278077; PMCID: PMC10315933.
28. Procter F. Rehabilitation of the burn patient. *Indian J Plast Surg*. 2010 Sep;43(Suppl): S101-13. doi: 10.4103/0970-0358.70730. PMID: 21321643; PMCID: PMC3038404.